


# Olfactory Mucosal Autografts and Rehabilitation for Chronic Traumatic Spinal Cord Injury

Neurorehabilitation and  
Neural Repair  
XX(X) 1–13  
© The Author(s) 2009  
Reprints and permission: <http://www.sagepub.com/journalsPermissions.nav>  
DOI: 10.1177/1545968309347685  
<http://nnr.sagepub.com>  


Carlos Lima, MD,<sup>1</sup> Pedro Escada, MD,<sup>1</sup> José Pratas-Vital, MD,<sup>1</sup>  
Catarina Branco, MD,<sup>2</sup> Carlo Alberto Arcangeli, MD,<sup>3</sup>  
Giovanna Lazzeri, MD,<sup>3</sup> Carlos Alberto Santana Maia, MD,<sup>4</sup>  
Clara Capucho, MD,<sup>1</sup> Armando Hasse-Ferreira, MD,<sup>1</sup> and  
Jean D. Peduzzi, PhD<sup>5</sup>

## Abstract

**Background/objective.** Basic science advances in spinal cord injury (SCI) are leading to novel clinical approaches. The authors report a prospective, uncontrolled pilot study of the safety and outcomes of implanting olfactory mucosal autografts (OMA) in 20 patients with chronic, sensorimotor complete or motor complete SCI. **Methods.** Seven paraplegic and 13 tetraplegic subjects (17 men and 3 women; 19–37 years old) who sustained a traumatic SCI 18 to 189 months previously (mean = 49 months) were enrolled. Preoperative rehabilitation that emphasized lower extremity stepping using either overground walking training or a robotic weight-supported treadmill training was provided for 25 to 39 hours per week for a median of 4 months at 3 sites. No change in ASIA Impairment Scale (AIS) motor scores for the lower extremities or AIS grades of completeness was found. OMAs were transplanted into 1.3- to 4-cm lesions at C4–T12 neurological levels after partial scar removal. Therapy was continued postoperatively. Preoperative and postoperative assessments included AIS scores and classification, electromyography (EMG) of attempted voluntary contractions, somatosensory evoked potentials (SSEP), urodynamic studies with sphincter EMG, spinal cord magnetic resonance imaging (MRI), and otolaryngology and psychology evaluations. The Functional Independence Measure (FIM) and Walking Index for Spinal Cord Injury (WISCI) were obtained in 13 patients. **Results.** All patients survived and recovered olfaction. One patient was rehospitalized for aseptic meningitis. Minor adverse events occurred in 4 others. The mean duration of follow-up was 27.7 months (range = 12–45 months). By MRI, the lesion site was filled in all patients with no neoplastic overgrowth or syringomyelia. AIS grades improved in 11 of 20 patients, 6 (A → C), 3 (B → C), and 2 (A → B), and declined in 1 (B → A). Improvements included new voluntary EMG responses (15 patients) and SSEPs (4 patients). Scores improved in the FIM and WISCI (13/13 tested), and urodynamic responses improved in 5 patients. **Conclusion.** OMA is feasible, relatively safe, and possibly beneficial in people with chronic SCI when combined with postoperative rehabilitation. Future controlled trials may need to include a lengthy and intensive rehabilitation arm as a control.

## Keywords

spinal cord injury, human, transplant, olfactory mucosa, regeneration, olfactory ensheathing cells, neural stem cells, rehabilitation

## Introduction

Advances from experimental animal research are translating into clinical trials using stem cells and other cells/tissue for severe spinal cord injury (SCI), a condition previously thought to be hopeless. The olfactory mucosa contains neural stem cells (NSCs) and olfactory ensheathing cells (OECs).<sup>1–4</sup> Rats with complete or partial spinal cord transections demonstrate functional improvement after transplant of olfactory mucosa,<sup>5</sup> olfactory mucosa-derived NSCs,<sup>6,7</sup> or olfactory mucosa-derived OECs.<sup>8–10</sup> Because olfactory mucosa contains SCI repair-promoting cells (NSCs and OECs) and is readily accessible with minimally invasive techniques,<sup>11,12</sup> a human pilot clinical study was done to

determine the safety and feasibility of olfactory mucosa autografts (OMAs) in severe, chronic traumatic SCI.<sup>12</sup> We

<sup>1</sup>Hospital de Egas Moniz, Centro Hospitalar de Lisboa Ocidental, Lisbon, Portugal

<sup>2</sup>Hospital de S. Sebastião, Feira, Portugal

<sup>3</sup>Centro Giusti, Istituto di Medicina Fisica e Riabilitazione, Firenze, Italy

<sup>4</sup>Centro de Medicina de Reabilitação da Região Centro, Rovisco Pais, Tocha, Cantanhede, Portugal

<sup>5</sup>Wayne State University Medical School, Detroit, Michigan, USA

### Corresponding Author:

Carlos Lima, Hospital de Egas Moniz, Centro Hospitalar de Lisboa Ocidental, EPE, Rua da Junqueira, 126, 1349-019 Lisbon, Portugal  
E-mail: [carlosvlima@sapo.pt](mailto:carlosvlima@sapo.pt)

found that the OMA procedure was safe and feasible. Two of 7 subjects improved from ASIA Impairment Scale (AIS) grade A to C. Interpretation of results was limited by the small number of patients and the lack of a control group. The potential improvement of these 7 OMA patients was constrained by the lack of an intense rehabilitation program and uncertainty about the optimal type of rehabilitation. We hypothesized that 3 components are critical for functional improvement after complete SCI: (a) OMA containing NSCs, (b) graft site management, and (c) an intense rehabilitation program.

First, olfactory mucosa is believed to be an ideal graft for SCI because it can be acquired autologously with minimally invasive techniques, and pieces large enough to fill a 3- to 4-cm cavity can be obtained. Using a person's own olfactory tissue may allow NSCs to integrate in a controlled manner without rejection or tumor formation that limits embryonic stem cell use. Unlike mesenchymal cells, Schwann cells, and OECs used for chronic SCI,<sup>13-15</sup> the normal course of the olfactory mucosa NSCs includes neurons. In fact, the olfactory system has the fastest rate of neurogenesis in the adult nervous system.

Second, the graft site must be modified before the graft is implanted. Preparing the injury site for grafting is in some cases technically challenging and may require several hours of surgery. The scar varies in composition (astrocytic, fibrotic, or mixed) and thickness.<sup>12,16,17</sup> Large cysts, multiple small cysts, or no cysts may be present. It is necessary to partially remove the scar superiorly and inferiorly to allow for transplant integration and bridging. In some cases only scar tissue remains at the injury site and must be removed.

Third, extended intense rehabilitation may be essential for recovery to strengthen physical components such as the skeletal, muscular, and vascular systems and to remodel the neural circuitry. It was unclear at the start of this study as to what would be the most effective rehabilitation program to promote recovery after NSC therapy. Repetition of unskilled movements,<sup>18,19</sup> strength training,<sup>20</sup> or exercise training<sup>21,22</sup> alone is not sufficient to induce motor map reorganization that is crucial to functional improvement after injury. In fact, SCI results in a disconnection syndrome that not only severs brain–spinal cord connections but also circuitry all over the neuraxis (eg, cortex–OMA).<sup>23</sup> The rehabilitation that seemed to be the most effective in combination with OMA was overground ambulation, called BIONT (brain-initiated overground nonrobotic/nonweight supported training), which allows compensatory or novel walking patterns. Body weight–supported treadmill training (BWSTT) has also been considered as a potential therapy.

The main objective of the study is to determine the safety and efficacy of OMA in an additional 20 patients with chronic, severe SCI in humans enrolled at 1 of 3 different

rehabilitation programs, which allowed us to compare BIONT with robotic BWSTT for intensive training.

## Materials and Methods

### *Patient Selection and Inclusion Criteria*

This phase I/II nonrandomized, noncontrolled prospective open-label study was approved by the Ethics Committee of the Hospital Egas Moniz, Centro Hospitalar de Lisboa Ocidental, Lisbon, Portugal, and meets the requirements of national agencies and ethical standards. All procedures were performed after obtaining written informed consent. Written consent included permission to culture and analyze a biopsy from the tissue to be grafted. Patients were fully aware of the experimental nature of the treatment, unclear outcomes, and possible side effects such as pain, spasticity, autonomic dysreflexia, worsening of motor or sensory function, infection, and unforeseen adverse events.

Patients were selected among individuals who had an SCI more than 1 year previously, were chronically paraplegic or tetraplegic, and were referred by Portuguese and Italian rehabilitation centers that specialize in the treatment of people with SCIs between April 2003 and December 2006 (Table 1). Costs for surgery and rehabilitation were paid by their respective governments. The rationale for selecting chronic (more than 12 months) SCI patients was to circumvent spontaneous recovery bias.

The inclusion criteria were the following: grade A or B on the AIS, age  $\geq 18$  and  $\leq 40$  years, presence of a cervical spinal cord lesion  $\leq 3$  cm or thoracic spinal cord lesion  $\leq 4$  cm, absence of significant nasal and paranasal sinus pathology, and absence of additional serious medical problems, brain disease, or psychological disturbance.

Twenty patients were enrolled in the study (17 men and 3 women). The mean age of the patients was  $30.2 \pm 5.7$  years. Demographic data and clinical and imaging/radiological characteristics of the patients are presented in Table 1. Lesions resulted from road traffic accidents in 14 patients, sports accidents in 4, and work-related accidents in 2 patients. Lesions varied between 1.3 and 4 cm in the maximum vertical axis as measured on both the T1 and T2 weighted magnetic resonance imaging (MRI). Fifteen patients were AIS grade A, and 5 patients were AIS grade B. One patient (patient 12) was accepted with low SCI because a recent publication showed reversal of severely denervated muscle after electrical stimulation.<sup>24</sup> Transplants were done from 18 to 189 months after injury (mean = 49 months). Sham operations were not considered because of the difficulty of ethical justification as this would entail an increased risk for the placebo group.<sup>25</sup>

**Table 1.** Demographic, Clinical, and Neurological Features of the Patients

Patient	Sex	Age (Years)	Months Post-SCI	SCI Level	P/T	Length of Lesion	AIS Grade
1	Male	31	43	C8	T	2.5	A
2	Female	21	20	T5	P	2.0	A
3	Male	26	18	C4	T	2.0	A
4	Male	37	20	C4	T	3.0	A
5	Male	33	189	C7	T	1.3	B
6	Male	20	52	C5	T	1.5	A
7	Male	34	123	T6	P	2.0	A
8	Male	27	28	C5	T	1.5	B
9	Male	22	33	T6	P	2.0	A
10	Male	24	28	T5	P	4.0	A
11	Male	35	35	T6	P	4.0	A
12	Male	30	60	T12	P	3.0	A
13	Male	31	24	C6	T	2.5	A
14	Male	24	43	C6	T	3.0	B
15	Female	37	101	C6	T	2.5	B
16	Male	23	38	C4	T	3.0	A
17	Male	33	40	C4	T	1.8	A
18	Male	25	27	C4	T	3.0	A
19	Male	30	32	T9	P	2.5	A
20	Female	19	33	C4	T	2.5	B

Abbreviations: SCI, spinal cord injury; P, paraplegic; T, tetraplegic; C, cervical; T, thoracic; AIS, ASIA Impairment Scale.

## Operation

Briefly, pieces of olfactory mucosa were removed, cut in small pieces, and grafted into the spinal cord lesion site after performing a laminectomy. The detailed protocol for transplantation and surgical procedure has been reported previously.<sup>12</sup> Microbiological examinations of the nasal cavities were performed routinely before and at the beginning of the operation. Specimens of the olfactory mucosa graft and scar tissue removed from the spinal cord were examined for histopathological and immunocytological purposes. In 6 cases, the olfactory mucosa graft specimens were cultured to derive NSCs.

## Preoperative and Postoperative Rehabilitation

All patients had preoperative rehabilitation ( $31.8 \pm 6.8$  h/wk with a mean duration of  $34.7 \pm 30$  weeks) and postoperative rehabilitation ( $32.7 \pm 5.2$  h/wk with a mean duration of  $92 \pm 37.6$  weeks). The preoperative rehabilitation was carried out up to the time immediately prior to the operation (maximum 7-day delay). Baseline measures were determined after the preoperative rehabilitation, which was intended to ensure a stabilized neurological status. The rehabilitation included physical therapy strategies for encouraging motor function at and below the lesion, enabling walking training as soon as possible. The rehabilitation program at all 3 centers consisted of the following: 2 hours of passive, assisted range of motion and strengthening exercises; 2 to 3 hours of functional training for balance, posture, standing, and

transfers; and 2 to 3 hours of pre-gait and gait activities. With regard to the walking training strategies, the Centro de Medicina de Reabilitação Rovisco Pais (RP), Tocha, Portugal, rehabilitation center focused on robotic-assisted bodyweight-support treadmill training (BWSST, Lokomat) for subjects 2 to 6, 8, and 11; and the Serviço de Medicina Física e de Reabilitação do Hospital S. Sebastião (SS), Feira, Portugal (subjects 1, 7, 9, 10, and 12) and Centro Giusti (CG), Florence, Italy (subjects 13-20) rehabilitation centers performed BIONT. BIONT is an assisted overground walking training, with loading on the hips, knees, and feet to promote sensorimotor biofeedback. There is freedom of movement (unrestricted by braces and other rigid bodyweight suspension systems) to allow the development of new, atypical motor patterns that may induce functional connections with supraspinal centers. BIONT focuses on the affected and nonaffected parts of the body.

## Outcome Measures

Safety and efficacy measures are presented in Table 2. Any improvement in the AIS grade scale or in the lower extremity motor scores is considered as evidence for true gains because motor scores were 0 in the legs of patients after preoperative rehabilitation.

Preoperative and postoperative assessments included the AIS neurological exam as described in International Standards for Neurological and Functional Classification of Spinal Cord Injury Patients<sup>26</sup>; standard electromyography (EMG) after asking the subject to move particular muscles

**Table 2.** Outcome Measures

Safety Measures	Efficacy Measures
Mortality	Ability to improve AIS grade
Incidence of complications	Variation in the ASIA scores
	Percentage of patients recovering deep anal sensation
Readmission rate	Percentage of patients recovering anal sphincter control
Percentage of patients with worsening in the ASIA scale grade	Percentage of patients recovering bladder sensation
Percentage of patients not recovering olfaction	Percentage of patients recovering bladder sphincter control
	Variation in the FIM measures
	Variation in the WISCI measures

Abbreviations: AIS, ASIA Impairment Scale; FIM, Functional Independence Measure; WISCI, Walking Index for Spinal Cord Injury.

and somatosensory evoked potentials (SSEP, cortically recorded after tibial nerve stimulation); urodynamic studies; full spinal cord MRI scan; otolaryngological evaluation including a general ear, nose, and throat examination, nasal endoscopy, olfactory evaluation, and computed tomography (CT) scan of the nose and paranasal sinuses; and psychological assessment. Psychological testing aimed to detect conditions such as active psychosis, major depression, anxiety disorder, severe mood disorder, suicidal behavior, alcohol addiction, drug addiction, low cognitive resources, and unrealistic expectations about treatment results.

All preoperative and postoperative neurological assessments were done unblinded in each rehabilitation center by the same trained SCI clinician and scheduled prior to OMA. The assessors were trained specifically for AIS (ASIA) assessments.<sup>27</sup> To reduce bias, the transplanted patients and the other SCI patients treated in each center were assessed in the same sessions. Eurotrials Scientific Consultants (Lisbon, Portugal) collected and analyzed data from each center.

The patients from rehabilitation centers SS and CG were also assessed for Functional Independence Measure (FIM)<sup>28,29</sup> and Walking Index for Spinal Cord Injury<sup>30</sup> (WISCI) scales. Pain was assessed via interviews asking the patients to identify painful areas, to describe the pain using standard descriptors, and to identify temporal aspects of pain. Spasticity was evaluated clinically. Neurological status of the patients was evaluated every 6 months after OMA. The mean duration for follow-up was 27.7 months (range = 12-45 months) postoperatively.

### Statistical Analysis

The statistical power consideration given the sample size limitation ( $N = 20$ ) required implementation of nonparametric

exact tests rather than asymptotic parametric tests. Nonparametric Wilcoxon signed rank test was employed to test the existence of any statistically significant difference between premeasures and the last nonmissing postmeasurement values. The decision on the statistical significance of the findings was made using an  $\alpha$  level of .05.

## Results

### Safety Issues

There was no mortality in our series. All the patients recovered olfaction during the follow-up, 95% of them within 2 months. Five patients experienced adverse events resulting from the treatment. Three of these patients had minor complications that resolved spontaneously (subcutaneous collection of cerebrospinal fluid along the incision) or with simple treatments. One patient developed a late (1 year) irritable bowel syndrome that required dietary changes and medication.

One patient (patient 8) had a more severe complication requiring hospital readmission. He developed aseptic meningitis 2 weeks after surgery, associated with sensory and motor neurological deterioration, changing the AIS grade from B to A. MRI imaging showed evidence of spinal cord edema. The acute manifestations subsided in 3 weeks with vancomycin and dexamethasone. The patient recovered to AIS grade B in 2 months, but sensory status only partially recovered. This was the only patient who had a reduction in AIS grade.

### Efficacy

**AIS assessments.** The data obtained using the AIS and ASIA scores are summarized in Tables 3, 5, 6, 7, and 8. The estimated mean change was statistically significant ( $p < .01$ , Table 4) in all the neurological measures (motor arms, motor legs, light touch, and pin prick scores). The changes were assessed between the baseline and the last evaluation ( $28 \pm 11$  months). Eleven (55%) patients improved their AIS grades: 6 patients from grade A to grade C, 3 patients from grade B to grade C, and 2 patients from grade A to grade B (Table 3). Nine (45%) of the patients who scored 0 at baseline for lower extremities improved from 4 to 22 at the last evaluation, including distal segmental muscles exceeding 3 motor segments (Table 6).

Rehabilitation centers that focused on BIONT therapy (SS and CG) had patients with better motor recovery compared with the rehabilitation center that focused on BWSTT (RP; Figure 1).

Of the 15 patients without anal sensation at the baseline evaluation, 9 had recovered at the last follow-up: 5 patients in the first 12 months and the others later. Additionally, 6 ASIA grade A patients (patients 1, 7, 9, 10, 12, and 19)

**Table 3.** Summary of AIS Grades

Patient	Baseline	Postsurgery AIS Grade					LOCF
		6 Months	12 Months	18 Months	24-30 Months	36-48 Months	
1	A	A	B	C	C	C	C
2	A	A	A	A	—	—	A
3	A	A	A	A	A	—	A
4	A	A	A	A	A	—	A
5	B	C	C	B	B	—	B
6	A	A	A	A	A	—	A
7	A	A	A	B	C	—	C
8	B	A	A	A	—	—	A
9	A	B	C	C	C	—	C
10	A	A	A	A	B	—	B
11	A	A	A	A	—	—	A
12	A	A	B	C	—	—	C
13	A	A	A	A	A	C	C
14	B	B	B	B	C	C	C
15	B	A	A	B	C	C	C
16	A	A	A	A	A	A	A
17	A	A	A	A	A	B	B
18	A	A	A	A	A	—	A
19	A	A	C	—	—	—	C
20	B	B	C	—	—	—	C

Abbreviations: AIS, ASIA Impairment Scale; LOCF, last observation carried forward; —, no evaluation done.

**Table 4.** Summary of Outcome Measures

	Pre $\pm$ SD	Post $\pm$ SD	Post-Pre	N	Z
ASIA motor arms (tetraplegics)	19.0 $\pm$ 14.5	23.5 $\pm$ 13.3	4.54	13 <sup>a</sup>	-2.59
ASIA motor legs	0	4.95 $\pm$ 7.1	4.95	20 <sup>a</sup>	-2.67
Paraplegics	0	9.3 $\pm$ 8.8	9.3	7	
Tetraplegics	0	2.6 $\pm$ 4.9	2.6	13	
ASIA light touch	42.7 $\pm$ 19.5	60.7 $\pm$ 28.0	18.0	20 <sup>a</sup>	-2.82
Paraplegics	56.4 $\pm$ 10.5	80.0 $\pm$ 20.6	23.6	7	
Tetraplegics	35.4 $\pm$ 19.5	50.4 $\pm$ 26.5	15.0	13	
ASIA pin prick	38.9 $\pm$ 19.3	54.6 $\pm$ 29.8	15.75	20 <sup>a</sup>	-2.8
Paraplegics	56.1 $\pm$ 10.7	77.4 $\pm$ 22.3	21.3	7	
Tetraplegics	29.6 $\pm$ 16.4	42.4 $\pm$ 26.3	12.8	13	
WISCI	0.15 $\pm$ 0.38	7.3 $\pm$ 2.6	7.15	13 <sup>b</sup>	-3.19
Paraplegics	0	9.6 $\pm$ 1.5	9.6	5	
Tetraplegics	0.3 $\pm$ 0.5	5.9 $\pm$ 2.0	5.6	8	
FIM	71.8 $\pm$ 20.9	86.8 $\pm$ 25.9	15.0	13 <sup>b</sup>	-3.18
Paraplegics	90 $\pm$ 12.2	110 $\pm$ 9.0	20.0	5	
Tetraplegics	60.5 $\pm$ 16.9	72.3 $\pm$ 21.8	11.8	8	

Abbreviations: SD, standard deviation; WISCI, Walking Index for Spinal Cord Injury; FIM, Functional Independence Measure.

<sup>a</sup> $P \leq .001$ .

<sup>b</sup> $P \leq .01$ .

recovered superficial sensation at S4-S5 segments. Five of the 20 patients without voluntary anal contraction recovered: 1 patient in the first 12 months and the others later. Of the 15 patients without bladder sensation at the baseline evaluation, 5 recovered the sensation of bladder fullness: 1 patient in the first 12 months and the others later. Only 1 of the 20 patients without bladder control recovered, by the 22nd month after surgery.

**Functional and walking assessment.** Thirteen patients from 2 rehabilitation centers (SS and CG) were assessed for functional studies. All the patients had improvements in FIM and WISCI scores (Figure 1). The mean FIM scores changed from  $71 \pm 23$  at the baseline to  $85 \pm 28$  at the last follow-up ( $P < .01$ ). The WISCI scores changed from  $0.2 \pm 0.4$  at the baseline to  $7.4 \pm 2.6$  at the last follow-up ( $P < .01$ ). WISCI scores were higher and achieved earlier in

**Table 5.** ASIA Motor Arms—Tetraplegic Patients

Patient No.	Baseline	6 Months	12 Months	18 Months	24-30 Months	36-48 Months
1	46	48	50	50	50	50
3	9	11	11	8	8	
4	7	9	9	8	8	
5	48	48	48	48	47	
6	16	19	19	18	18	
8	20	16	18	18		
13	28	31	28		31	34
14	18	20	20			24
15	26	26	31	31		30
16	4	4	11			13
17	8	14	14			20
18	11	11	11	11	18	
20	6	10	18			
Mean	19	20.53	22.15	21.76	22.46	23.53
N	13	13	13	8	7	6

**Table 6.** ASIA Motor Legs

Patient No.	Baseline	6 Months	12 Months	18 Months	24-30 Months	36-48 Months
1	0	0	0	16	16	16
2	0	0	0	0		
3	0	0	0	0	0	
4	0	0	0	0	0	
5	0	1	2	0	0	
6	0	0	0	0	0	
7	0	0	0	0	14	
8	0	0	0	0		
9	0	12	12	20		
10	0	2	0	5	7	
11	0	0	0	0		
12	0	8	4	18		
13	0	6	0		6	8
14	0	0	0			4
15	0	0	0			6
16	0	0	0			0
17	0	0	0			0
18	0	0	0	0	0	
19	0	4	4			
20	0	2	0			
Mean	0	1.75	1.1	4.5	4.8	5.7
N	20	20	20	13	5	6

paraplegic than in tetraplegic patients ( $P < .01$ ). There was no difference between paraplegic and tetraplegic patients in the gain in FIM scores ( $P > .05$ ).

Hip flexor muscle recovery was observed initially at  $13 \pm 11$  months (patients 1, 7, 9, 10, 12, 13, 14, 15, and 19). Knee and ankle muscle recovery was observed initially at  $22 \pm 7$  months (patients 1, 7, 9, 10, 12, 13). This suggests a proximal-distal pattern of recovery.

Of the 13 patients assessed by functional studies, 1 paraplegic patient (patient 9) can ambulate with 2 crutches and

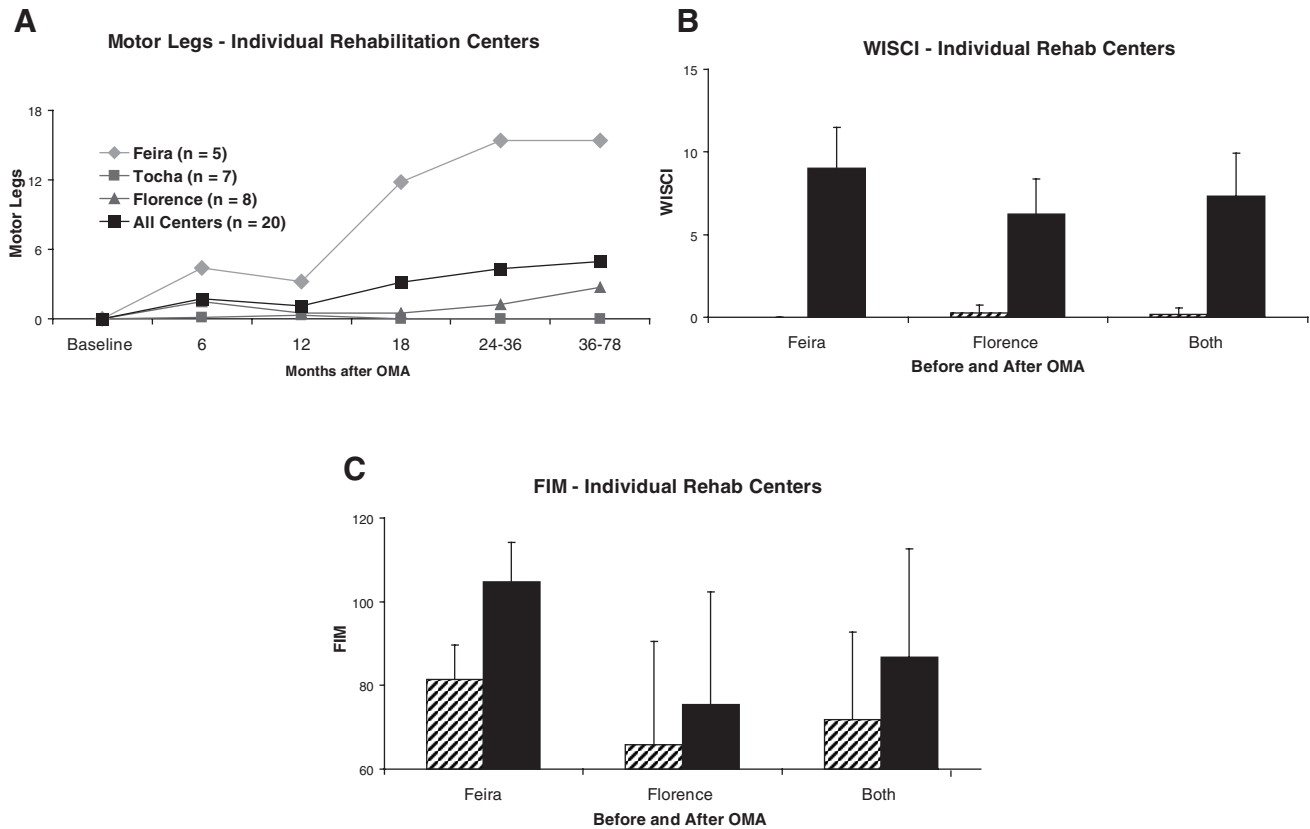
**Table 7.** ASIA Light Touch

Patient No.	Baseline	6 Months	12 Months	18 Months	24-30 Months	36-48 Months
1	28	38	68	88	94	100
2	48	48	48	46		
3	14	14	14	12	14	
4	17	21	14	14	13	
5	78	69	59	44	72	
6	39	16	20	17	21	
7	52	56	64	72	90	
8	64	47	45	54		
9	52	66	84	92		
10	48	56	60	73	85	
11	53	56	56	56		
12	76	76	83	97		
13	24	37	32		50	70
14	46	62	62			60
15	51	51	40			75
16	15	15	37			41
17	27	41	41			42
18	26	26	26	26	29	
19	66	66	88			
20	31	34	64			
Mean	42.7	44.75	50.25	53.15	52	64.67
N	20	20	20	13	9	6

**Table 8.** ASIA Pin Prick

Patient No.	Baseline	6 Months	12 Months	18 Months	24-30 Months	36-48 Months
1	28	38	68	88	94	100
2	48	48	48	46		
3	15	14	14	12	12	
4	15	24	12	12	12	
5	71	54	43	35	56	
6	35	20	19	16	18	
7	52	56	64	72	90	
8	16	21	21	19		
9	52	66	88	100	104	
10	48	56	60	73	85	
11	51	48	54	54		
12	76	76	83	97		
13	22	32	32		35	40
14	42	34	34			64
15	49	49	46			72
16	15	15	32			31
17	24	39	39			39
18	25	25	25	25	32	
19	66	66	66			
20	28	34	56			
Mean	38.9	40.75	45.2	49.92	53.8	57.67
N	20	20	20	13	10	6

knee braces with no physical assistance and 10 other patients can ambulate with walkers with or without braces with physical assistance. One tetraplegic patient (patient 13) ambulates with a walker, without knee braces or physical assistance.



**Figure 1.** ASIA Motor Legs scores and WISCI and FIM after OMA with rehabilitation at individual centers. (A) ASIA motor legs scores at given times after OMA. After preoperative rehabilitation (mean = 8 months; range = 1-27 months), all 20 patients had a motor leg scores of 0. The greatest improvement after OMA was the primarily paraplegic patients receiving rehabilitation at SS (◆) with 5/5 patients improving, some improvement primarily in tetraplegics at GC (▲) with 4/8 patients improving, and no improvement (7/7 patients) in the primarily tetraplegics at RP (□). (B) WISCI scores ( $\pm$ SD) before OMA (cross-hatching) and after OMA (solid) with rehabilitation at SS and/or GC. (C) FIM scores ( $\pm$ SD) before OMA (cross-hatching) and after OMA (solid) with rehabilitation at SS and/or GC. WISCI, Walking Index for Spinal Cord Injury; FIM, Functional Independence Measure; OMA, olfactory mucosa autograft; SS, Hospital S. Sebastião, Feira, Portugal; CG, Centro Giusti, Florence, Italy; RP, Rovisco Pais, Tocha, Portugal.

**Electrophysiological assessments.** New voluntary activity in response to voluntary effort was documented by EMG in 15 (75%) of the patients. In 6 tetraplegic patients (patients 1, 6, 8, 13, 16, and 20) and in 5 paraplegic patients (patients 7, 9, 10, 12, and 19) voluntary motor potentials were found in lower limb muscles.

New SSEP findings by tibial nerve stimulation were recorded at a cortical level after tibial nerve stimulation in 4 patients (patients 2, 4, 14, and 16). An example of this activity is shown for RP patient 2 (see Figure 2).

**Urodynamic studies.** In 5 postoperative urodynamic studies, patients were now able to detect a full bladder (patients 1, 7, 9, 10, and 12). Particularly important are the result obtained in patient 9, with EMG evidence of sphincter voluntary contraction.

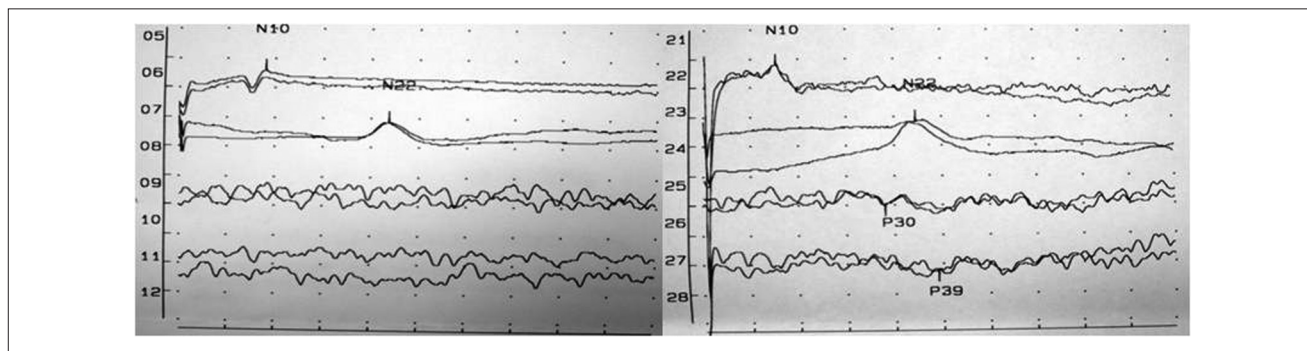
**Magnetic resonance imaging.** As in our previous study,<sup>12</sup> MRI showed a complete or almost complete filling of the lesion site in all patients, suggesting long-term graft viability. The grafted area has a “salt and pepper,”<sup>12</sup> “popcorn,” or

a mixed appearance. The “popcorn” appearance, a more heterogeneous and multilobulated pattern, is usually observed in the more chronic stage after the surgical treatment (Figure 3). There was no evidence of neoplastic tissue overgrowth or syringomyelia.

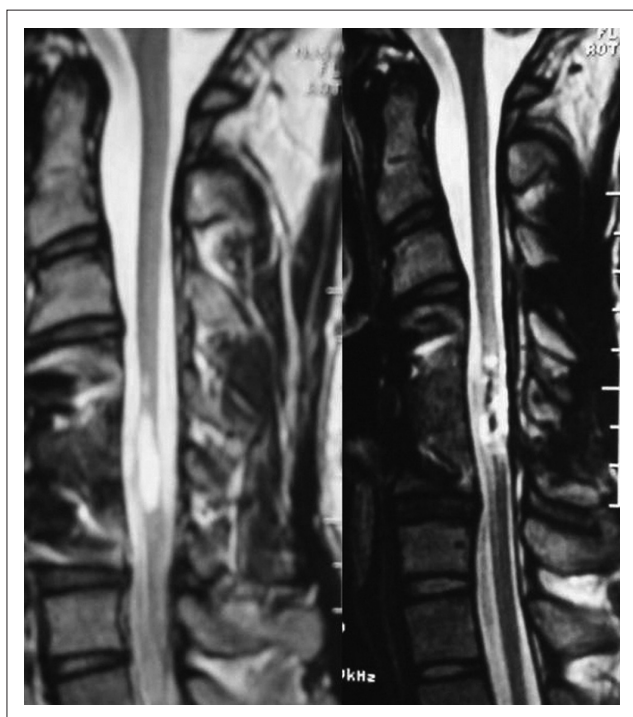
**Pain and spasticity.** Most of the pain reported in the study was musculoskeletal or surgical pain that resolved normally. One patient developed a late (1 year) irritable bowel syndrome, which could be also interpreted as a visceral neuropathic pain that subsided 5 years after surgery. No significant changes were observed in spasticity in the first weeks after surgery, as found in other studies.<sup>31,32</sup>

### Spinal Cord Scar and Olfactory Mucosa Analysis

The most common observation was a scar of mixed composition containing astrocytic processes, fibroblasts, collagen, and laminin, with peripheral type axons interspersed, and single or multiple cystic cavities in different proportions.



**Figure 2.** Somatosensory evoked potential findings (left = pre-OMA; right = Post-OMA). Recordings after tibial nerve stimulation of the new P30 (cervical) and P39 (cortical) waves 8 months after OMA in patient 2 (AIS grade A, T5 paraplegic patient, RP) in spite of no changes in AIS and ASIA scores. OMA, olfactory mucosa autograft; AIS, ASIA Impairment Scale.



**Figure 3.** MRI findings. Left, preoperative T2-weighted sagittal MRI from patient 6 (AIS grade A, C5 tetraplegic patient) revealing a cystic lesion. Right, postoperative T2-weighted sagittal MRI from the same patient showing “popcorn” appearance in chronic stages. MRI, magnetic resonance imaging; AIS, ASIA Impairment Scale.

Very rarely neurons were found, and in many cases we observed macrophagic infiltration predominantly within the glial rather than the fibrotic component of the scar. In thoracic lesions, areas of collagen and peripheral type axons were marginally involved in astrocytic glial fibers, whereas in cervical lesions, a single cyst cavity lined by astrocytic glial scar with variable collagen content from the walls of surrounding vessels was found. In the most severe SCI cases,

there was laceration of the dura mater, and the spinal canal was filled with bone fragments and large amounts of collagen, particularly in some thoracic patients.

Six of the olfactory mucosa biopsy samples were selectively cultured, and neurons were generated from the stem cells. Graft culture after dissociation of the olfactory mucosa biopsies revealed about 100 000 stem cells in each cubic millimeter of olfactory mucosa, which is the typical size of each piece of olfactory mucosa tissue implanted.<sup>33</sup> The number of pieces required to fill a cavity (generally more than 30) was dependent on the size of the cavity in the spinal cord after removing some of the scar tissue. *Methicillin-resistant Staphylococcus aureus* (MRSA) contamination was present in the olfactory mucosa graft biopsy from patient 8 even though the preoperative testing was negative.

## Discussion

In this study, the safety and feasibility of OMA was supported. There was only 1 serious adverse event of aseptic meningitis. Close monitoring of patients using neurological, functional, and electrophysiological testing demonstrated indications of efficacy in a number of patients that seemed to relate to OMA combined with the BIONT rehabilitation program as opposed to OMA and BWSTT as the rehabilitation intervention.

### AIS and ASIA Changes

After preoperative rehabilitation, 15 patients were AIS grade A and 5 were AIS grade B. Subsequent to OMA and postoperative rehabilitation, 11 (8 tetraplegics and 3 paraplegics) improved in AIS grade. Six improved by 2 grades and 5 by 1 grade. All the patients having rehabilitation at SS improved in AIS grade along with most of those who had rehabilitation at GC (primarily tetraplegic patients). No improvement was observed in AIS grade in the predominantly tetraplegic patients at RP receiving BWSTT. There



were similar differences in the changes in ASIA scores. All patients had motor scores of 0 for the legs after preoperative rehabilitation, and there was no change in primarily tetraplegic OMA patients at RP, an average increase of 2.75 in the primarily tetraplegic OMA patients receiving therapy at GC, and a striking mean increase of 15.4 in the primarily paraplegic OMA patients at SS. No change was observed in motor arms in RP tetraplegic OMA patients; there was a mean increase of 8 in tetraplegic OMA patients at GC. Similar results depending on the rehabilitation center were found in sensory scores for light touch (LT) and pin prick (PP): RP: (LT = -5.3; PP = -4.9), GC (LT = 22.9; PP = 16.1), and SS (LT = 42.8; PP = 44). The mean overall changes observed in ASIA scores are beyond the minimal detectable changes (motor = 0.29; sensory pinprick = 7.8; sensory light touch = 12.95) as recently reported.<sup>33</sup> Although results are striking at 2 of the centers using BIONT rehabilitation, functional changes are most important to the patients.

### Functional Improvement

Functional changes were measured with urodynamic studies and WISCI and FIM scores. Bladder sensation or control can dramatically modify the quality of life of these patients. One patient recovered bladder control at almost 2 years after OMA, and 25% of the patients could now accurately detect when the bladder was full during urodynamic studies.

All the 13 patients in whom WISCI was measured demonstrated improvement. Slightly greater improvement was observed in the paraplegic patients, with the greatest improvement in patient 9, who went from no mobility to being able to ambulate 10 m with braces and crutches without assistance. The results are clinically relevant because they include recovery of motor voluntary activity in lower limbs, both proximal and distal, which are reflected by the gait improvements in a significant proportion of the patients. Although independent walking of a previous motor complete SCI patient might be an achievable goal, any recovery even with modest changes can have profound effects on the quality of life in the patients. This is particularly true in cervical SCI where individuals who can crawl by themselves provide some degree of locomotion independence in case of an emergency. There was a correlation between motor leg scores and WISCI ( $r = .69$ ;  $n = 8$ ). Because the patients were aware of their treatment, their motivation to improve their function, prevent immobility related side effects, and improve transfers may have been high.

The 13 who had FIM scores measured also improved, and the improvement correlated with their WISCI scores ( $r = .75$ ;  $n = 13$ ), motor arms ( $r = .83$ ;  $n = 8$ ), and motor legs ( $r = .75$ ;  $n = 13$ ). Again greater absolute improvement was observed in the paraplegic patients. Curt et al<sup>34</sup> found that some functional improvement as measured by Spinal Cord Independence Measure can occur in the first year after injury

in complete SCI patients without concomitant changes in neurological condition or conductivity, so it was important to determine if there were any electrophysiological measures that point to neural repair.

### Electrophysiological Evidence of Recovery

In 15 of the 20 patients, we demonstrated EMG activity in muscles on command below the level of injury, where previously no signal was present. This new voluntary control of muscles suggests that OMA had mediated a change across the injury site. This is further supported by the finding of SSEPs in some patients, objectively validating conductivity SCI repair.<sup>34</sup>

### Safety Concerns and Adverse Events

A particular area of concern was the possibility of the introduction of pathogens in using a mucosa that is normally exposed to the air. We routinely perform preoperative and intraoperative microbiological examination of the nasal cavities and tissue graft. One of the 20 patients (patient 8) developed, 2 weeks after surgery, an aseptic meningitis syndrome (cerebrospinal fluid profile showed a high protein content and low glucose level, <100 cell count, predominant mononuclear cells, lymphocytes, and monocytes, with negative microbiological assays) and negative microbiological assay of blood, associated with MRI evidence of spinal cord edema and sensory and motor neurological deterioration. This patient had an intraoperative MRSA-positive nasal swab and graft examination (culturing required several days) following a negative preoperative microbiological evaluation. Secondary contamination due to surgical instrumentation when the graft passes through nasal pathways was suspected.

New visceral pain was present in 1 tetraplegic patient (patient 1) at 1 year postsurgery and interfered with daily activities. It was relieved with diet and medication (antidepressants and spasmolytics). It was strikingly postural dependent subsiding with recumbent position and was present during the current follow-up but subsided sharply 5 years after surgery. Because this patient was AIS grade A before OMA we do not know if this was associated with sensory and autonomic recovery or was due to maladaptive plasticity mechanisms after tissue transplantation.<sup>35</sup> The prevalence of pain in chronic SCI is high but the visceral one is low (5%).<sup>36</sup> Temporary musculoskeletal pain and spasm associated with physiotherapy efforts was present in several patients but neuropathic pain was not reported in any other patient.

### Improbability of Spontaneous Recovery for Chronic, Complete SCI

Spontaneous late recovery is unlikely to be responsible for the gains reported because OMA was performed at least

18 months or more after SCI. It is reported that only 5.6% of AIS A (32/571 patients) and 20.2% (23/114 patients) of AIS B improved in grade from year 1 to 5 after SCI.<sup>37</sup> In this study, 53.3% of AIS A and 60% of AIS B improved in grade. Because the 4 patients who improved the most in ASIA motor score for the legs (patients 1, 7, 9, and 12) had the OMA surgery performed more than 2 years after injury (3½, 10, 2½, and 5 years, respectively), spontaneous recovery is highly improbable. This result also suggests that the time after injury is not a critical factor in performing the OMA procedure.

### *Rehabilitation Alone Insufficient for Recovery in Chronic, Complete SCI*

One of the limitations of this study is that there was no control group with rehabilitation alone to separate the effects of rehabilitation and OMA and rehabilitation. However, 8/20 had about a year or more of intense rehabilitation before the OMA with no change in AIS grade, and their ASIA motor legs remained at 0. This strongly suggests that rehabilitation alone was not sufficient for these patients with complete SCI. Six of the 8 patients with a year or more of preoperative rehabilitation improved in AIS grade and had gains in ASIA motor leg scores (mean 13.5) subsequent to OMA and BIONT rehabilitation. Some recovery was present in 4 out of 6 of these patients at the 6-month evaluation after OMA. Again this suggests that the rehabilitation alone was not responsible for this recovery.

### *OMA Alone Insufficient for Recovery in Chronic, Complete SCI*

OMA alone is not likely to be sufficient to improve function after a complete SCI. One of the important findings of this study is that rehabilitation, and possibly a particular type of rehabilitation program, has to be combined with OMA to get improvement. Although all rehabilitation programs probably greatly increase the health of the individual, functional gains as measured by the outcome measures used in this study and, most important, new voluntary muscle control were only observed in the BIONT groups at the SS and CG sites after OMA. No motor recovery was found in the robotic BWSTT program (RP), which primarily focused on the affected part of the body. For a OMA procedure performed in India, patients who were only given instructions to follow a rehabilitation program at home or at rehabilitation centers did not show any ASIA score improvement.<sup>38</sup> Their compliance and the intensity of therapy is unknown. The amount of recovery of OMA patients who received BIONT rehabilitation at SS and CG was also greater than the first 7 OMA patients we previously reported.<sup>12</sup> These findings stress the importance of not only combining OMA with rehabilitation but also that a BIONT-type rehabilitation

program that focuses on the whole body may be necessary for improvement. The BIONT rehabilitation program is specifically goal directed at walking. Braces and support are minimized over time and load bearing is encouraged to achieve ambulation.<sup>39,40</sup> The use of muscle groups not normally used in walking is encouraged,<sup>41</sup> and the preinjury pattern of walking is not attempted. Other tissue/cell therapies, such as autologous bone marrow transplantation,<sup>13,42</sup> fibroblast growth factor,<sup>43</sup> and autologous Schwann cells,<sup>14</sup> for chronic complete SCI with no or other types of rehabilitation programs have not reported any improvements.

Recent studies in patients with chronic paraplegia confirm structural changes in the cerebral cortex and descending motor pathways including corticospinal tracts that are not directly connected to the spinal cord proving that the SCI represents a disconnection syndrome.<sup>23</sup> In SCI complete lesions, the creation of new neural pathways that mediate functional recovery require at least partial reconnection of anatomical circuits by scar removal and cellular transplantation strategies. Subsequent functional rewiring necessitates rehabilitation strategies to reorganize circuits in the brain and spinal cord for meaningful sensory–motor integration of new and/or remaining neural circuits<sup>44–46</sup> that may require a brain-initiated rehabilitation program such as BIONT.

### *Probable Mechanism of OMA Recovery*

Other studies demonstrate that it is unlikely that long tract regeneration (eg, corticospinal tracts) takes place in the mature mammalian nervous system after SCI. In hemisectioned spinal cord, new axonal sprouting connections with propriospinal neurons proximal to the lesion site occur with formation of new intraspinal circuits relaying cortical input to distal locomotor centers.<sup>47,48</sup> Accordingly, both modified and new neural pathways may mediate recovery in incomplete patients and presumably in complete patients after successful cell/tissue therapies. It is unrealistic to expect a restoration of neural tissue function to its original state. A reconnection by a repair/bridge mechanism provided by immature neurons with assistance from other cell types such as OECs and fibroblasts could provide a lesion site neuronal network relay station between both the rostral and caudal stumps of the spinal cord. Support for this idea is that neurons developed from the 6 olfactory mucosa biopsy samples cultured from our patients. The new surgical injury may also induce plasticity.

### *OMA as Source of Neural Stem Cells*

Stem cell treatment has the potential to be a major medical advance for SCI,<sup>5,49,50</sup> and several types of stem cells are available such as embryonic, fetal, umbilical cord blood cells, and adult stem cells (bone marrow mesenchymal cells, fat cells, brain subventricular zone, olfactory mucosa,

and many other tissue types). Adult stem cells allow autologous transplants that avoid the problems of rejection, neoplasia,<sup>51</sup> disease transmission,<sup>52-54</sup> graft-versus-host disease,<sup>55</sup> and ethical issues. In contrast to other readily available sources of adult stem cells, the normal fate of olfactory mucosa stem cells is to become neurons and support cells. Olfactory mucosa NSCs maintain telomerase activity and low apoptotic activity after several years in culture, and unlike hematopoietic stem cells and bone marrow mesenchymal cells, the capacity to replicate does not change with a person's age.<sup>56</sup> The olfactory mucosa is the only part of the adult nervous system capable of lifelong neurogenesis and axogenesis<sup>57</sup> that is readily accessible.<sup>11,12</sup> Neurons in the olfactory mucosa are continually being replaced by newly formed neurons.<sup>58,59</sup> In culture, the olfactory mucosa is a source of stem cells that can become neurons,<sup>1,3,4</sup> including motoneurons<sup>60</sup> and oligodendrocytes.<sup>61</sup>

Other cell types in the olfactory mucosa may assist stem cell derivatives in bridging the injury site. OECs that are also present in the olfactory mucosa may contribute to the repair process. OECs obtained from the olfactory mucosa<sup>8</sup> promote axonal remyelination and regeneration in the damaged spinal cord. Equally favorable results were obtained using pieces of the lamina propria of the olfactory mucosa or cultured nasal OECs.<sup>9,10</sup> OECs derived from the olfactory mucosa express a unique combination of developmentally important proteins not reported in olfactory bulb OECs.<sup>62</sup> It also seems that adding other cells to OEC cultures such as fibroblasts<sup>63</sup> or meningeal cells might increase the efficacy in SCI regeneration.<sup>64</sup>

### Theoretical Support for Scar Removal

The composition of the scar (astrocytic, fibrotic, or mixed) implies that it is a physical and molecular barrier to axon regeneration and neural circuitry repair. The thickness and sometimes huge expanse of scar tissue necessitates that before any cell bridging attempt, the scar should be surgically reduced to the point of not damaging normal tissue, which can be accomplished by careful microscopic dissection.

### Future Directions

Our studies offer strong support for the safety and feasibility of the OMA procedure. There are clear indications of efficacy based on neurological, functional, and electrophysiological testing that justify moving forward to a larger, controlled clinical trial. However, there are 3 important points to consider:

1. The technical challenges of OMA mean that expansion to other sites with limited resources should be approached conservatively. Our team prepared for

several years for this clinical study and proceeded slowly. Surgical techniques were perfected on cadavers. The nasal mucosa was examined in numerous cadavers to define the region where only olfactory mucosa is present. Given the complexity and invasiveness of the surgical procedure, the possibility of sham surgeries must be cautiously considered because of the risks involved.

2. New tests need to be developed for rapid recognition of olfactory tissue to prevent any respiratory tissue in the graft.
3. The OMA procedure must be combined with an intense rehabilitation program to obtain improvement. The design of a randomized controlled clinical trial will require 2 arms given our results. Prior to randomization, all subjects should receive an intensive and specific rehabilitation effort for up to several months. This phase will help reduce confounders of latent function that a rehabilitation effort may bring out.<sup>65</sup> One group would be randomized to continued rehabilitation and another group to the surgical procedure with OMA and rehabilitation. The specific rehabilitation intervention will require continued consideration, given the experience we describe with BIONT compared with robotic-assisted therapy. In addition, the effort at driving training-induced plasticity must be continued intensively for at least 2 to 3 years.

### Acknowledgments

We are grateful to Dr Bulent Ozkan from Wayne State University for assistance with the statistical analysis. We would also like to express our admiration for the OMA patients who pursued rehabilitation with such spirit and determination.

### Declaration of Conflicting Interests

The authors declared no potential conflicts of interests with respect to the authorship and/or publication of this article.

### Funding

The authors received no financial support for the research and/or authorship of this article.

### References

1. Calof AL, Mumm, JS, Rim PC, Shou J. The neuronal stem cell of the olfactory epithelium. *J Neurobiol.* 1998;36:190-205.
2. Huard JM, Youngentob SL, Goldstein BJ, Luskin MB, Schwob JE. Adult olfactory epithelium contains multipotent progenitors that give rise to neurons and non-neural cells. *J Comp Neurol.* 1998;400:469-486.
3. Roisen FJ, Klueber KM, Lu CL, et al. Adult human olfactory stem cells. *Brain Res.* 2001;890:11-22.
4. Murrell W, Feron F, Wetzig A, et al. Multipotent stem cells from adult olfactory mucosa. *Dev Dyn.* 2005;233:496-515.

5. Iwatsuki K, Yoshimine T, Kishima H, et al. Transplantation of olfactory mucosa following spinal cord injury promotes recovery in rats. *Neuroreport*. 2008;19:1249-1252.
6. Xiao M, Klueber KM, Lu C, et al. Human adult olfactory neural progenitors rescue axotomized rodent rubrospinal neurons and promote functional recovery. *Exp Neurol*. 2005;194:12-30.
7. Xiao M, Klueber KM, Guo Z, Lu C, Wang H, Roisen FJ. Human adult olfactory neural progenitors promote axotomized rubrospinal tract axonal reinnervation and locomotor recovery. *Neurobiol Dis*. 2007;26:363-374.
8. Kato T, Honmou O, Uede T, Hashi K, Kocsis JD. Transplantation of human olfactory ensheathing cells elicits remyelination of demyelinated rat spinal cord. *Glia*. 2000;30:209-218.
9. Lu J, Feron F, Ho SM, Mackay-Sim A, Waite PM. Transplantation of nasal olfactory tissue promotes partial recovery in paraplegic adult rats. *Brain Res*. 2001;889:344-357.
10. Lu J, Feron F, Mackay-Sim A, Waite PM. Olfactory ensheathing cells promote locomotor recovery after delayed transplantation into transected spinal cord. *Brain*. 2002;125:14-21.
11. Winstead W, Marshall CT, Lu CL, Klueber KM, Roisen FJ. Endoscopic biopsy of human olfactory epithelium as a source of progenitor cells. *Am J Rhinol*. 2005;19:83-90.
12. Lima C, Pratas-Vital J, Escada P, Hasse-Ferreira A, Capucho C, Peduzzi JD. Olfactory mucosa autografts in human spinal cord injury: a pilot clinical study. *J Spinal Cord Med*. 2006;29:191-203.
13. Sykova E, Homola A, Mazanec R, et al. Autologous bone marrow transplantation in patients with subacute and chronic spinal cord injury. *Cell Transplant*. 2006;15:675-687.
14. Saberi H, Moshayedi P, Aghayan HR, et al. Treatment of chronic thoracic spinal cord injury patients with autologous Schwann cell transplantation: an interim report on safety considerations and possible outcomes. *Neurosci Lett*. 2008;443:46-50.
15. Mackay-Sim A, Feron F, Cochrane J, et al. Autologous olfactory ensheathing cell transplantation in human paraplegia: a 3-year clinical trial. *Brain*. 2008;131:2376-2386.
16. Buss A, Brook GA, Kakulas B, et al. Gradual loss of myelin and formation of an astrocytic scar during Wallerian degeneration in the human spinal cord. *Brain*. 2004;127:34-44.
17. Buss A, Pech K, Kakulas BA, et al. Growth-modulating molecules are associated with invading Schwann cells and not astrocytes in human traumatic spinal cord injury. *Brain*. 2007;130:940-953.
18. Kleim JA, Barbay S, Nudo RJ. Functional reorganization of the rat motor cortex following motor skill learning. *J Neurophysiol*. 1998;80:3321-3325.
19. Plautz EJ, Milliken GW, Nudo RJ. Effects of repetitive motor training on movement representations in adult squirrel monkeys: role of use versus learning. *Neurobiol Learn Mem*. 2000;74:27-55.
20. Remple MS, Bruneau RM, VandenBerg PM, Goertzen C, Kleim JA. Sensitivity of cortical movement representations to motor experience: evidence that skill learning but not strength training induces cortical reorganization. *Behav Brain Res*. 2001;123:133-141.
21. Kleim JA, Cooper NR, VandenBerg PM. Exercise induces angiogenesis but does not alter movement representations within rat motor cortex. *Brain Res*. 2002;934:1-6.
22. Jensen JL, Marstrand PC, Nielsen JB. Motor skill training and strength training are associated with different plastic changes in the central nervous system. *J Appl Physiol*. 2005;99:1558-1568.
23. Wrigley PJ, Gustin SM, Macey PM, et al. Anatomical changes in human motor cortex and motor pathways following complete thoracic spinal cord injury. *Cereb Cortex*. 2009;19:224-232.
24. Boncompagni S, Kern H, Rossini K, et al. Structural differentiation of skeletal muscle fibers in the absence of innervation in humans. *Proc Natl Acad Sci USA*. 2007;104:19339-19344.
25. Lammertse D, Tuszynski MH, Steeves JD, et al. Guidelines for the conduct of clinical trials for spinal cord injury as developed by the ICCP panel: clinical trial design. *Spinal Cord*. 2007;45:232-242.
26. American Spinal Cord Association. *ASIA International Standards for Neurological Classification of Spinal Cord Injury, Revised*. Chicago, IL: American Spinal Cord Association; 2002.
27. American Spinal Cord Association. *ASIA International Standards for Neurological Classification of Spinal Cord Injury, Revised*. Chicago, IL: American Spinal Cord Association; 2003.
28. Ditunno JF Jr. Functional assessment measures in CNS trauma. *J Neurotrauma*. 1992;9(suppl 1):S301-S305.
29. Anderson K, Aito S, Atkins M, et al. Functional recovery measures for spinal cord injury: an evidence-based review for clinical practice and research. *J Spinal Cord Med*. 2008;31:133-144.
30. Ditunno JF Jr, Ditunno PL, Graziani V, et al. Walking Index for Spinal Cord Injury (WISCI): an international multicenter validity and reliability study. *Spinal Cord*. 2000;38:234-243.
31. Reier PJ. Cellular transplantation strategies for spinal cord injury and translational neurobiology. *NeuroRx*. 2004;1:424-451.
32. Dobkin BH, Curt A, Guest J. Cellular transplants in China: observational study from the largest human experiment in chronic spinal cord injury. *Neurorehabil Neural Repair*. 2006;20:5-13.
33. Carvalho AV, Lima C, Basto V, et al., inventors. Adult human neural stem/progenitor cells from the olfactory epithelium and olfactory lamina propria, isolation method, proliferation and differentiation in serum free culture medium and utilization for transplantation. Portugal patent WO/020611. 2007.
34. Curt A, Van Hedel HJ, Klaus D, Dietz V. Recovery from a spinal cord injury: significance of compensation, neural plasticity, and repair. *J Neurotrauma*. 2008;25:677-685.
35. Magavi SSP, Lois C. Transplanted neurons form both normal and ectopic projections in the adult brain. *Dev Neurobiol*. 2008;68:1527-1537.
36. Siddall PJ, McClelland JM, Rutkowski SB, Cousins MJ. A longitudinal study of the prevalence and characteristics of pain in the first 5 years following spinal cord injury. *Pain*. 2003;103:249-257.

37. Kirshblum S, Millis S, McKinley W, Tulskey D. Late neurologic recovery after traumatic spinal cord injury. *Arch Phys Med Rehabil.* 2004;85:1811-1817.
38. Chhabra HS, Lima C, Sachdeva S, et al. Autologous mucosal transplant in chronic spinal cord injury: an Indian pilot study [published online ahead of print June 2, 2009]. *Spinal Cord.* doi:10.1038/sc.2009.54.
39. Dietz V, Muller R, Colombo G. Locomotor activity in spinal man: significance of afferent input from joint and load receptors. *Brain.* 2002;125:2626-2634.
40. Dietz V, Harkema SJ. Locomotor activity in spinal cord-injured persons. *J Appl Physiol.* 2004;96:1954-1960.
41. Scivoletto G, Ivanenko Y, Morganti B, et al. Plasticity of spinal centers in spinal cord injury patients: new concepts for gait evaluation and training. *Neurorehabil Neural Repair.* 2007;21:358-365.
42. Yoon SH, Shim YS, Park YH, et al. Complete spinal cord injury treatment using autologous bone marrow cell transplantation and bone marrow stimulation with granulocyte macrophage-colony stimulating factor: phase I/II clinical trial. *Stem Cells.* 2007;25:2066-2073.
43. Wu JC, Huang WC, Tsai YA, Chen YC, Cheng H. Nerve repair using acidic fibroblast growth factor in human cervical spinal cord injury: a preliminary phase I clinical study. *J Neurosurg Spine.* 2008;8:208-214.
44. Dobkin BH. Functional rewiring of brain and spinal cord after injury: the three Rs of neural repair and neurological rehabilitation. *Curr Opin Neurol.* 2000;13:655-659.
45. Cramer SC, Lastra L, Lacourse MG, Cohen MJ. Brain motor system function after chronic, complete spinal cord injury. *Brain.* 2005;128:2941-2950.
46. Behrman AL, Bowden MG, Nair PM. Neuroplasticity after spinal cord injury and training: an emerging paradigm shift in rehabilitation and walking recovery. *Phys Ther.* 2006;86:1406-1425.
47. Bareyre FM, Kerschensteiner M, Raineteau O, Mettenleiter TC, Weinmann O, Schwab ME. The injured spinal cord spontaneously forms a new intraspinal circuit in adult rats. *Nat Neurosci.* 2004;7:269-277.
48. Courtine G, Song B, Roy RR, et al. Recovery of supraspinal control of stepping via indirect propriospinal relay connections after spinal cord injury. *Nat Med.* 2008;14:69-74.
49. Tarasenko YI, Gao J, Nie L, et al. Human fetal neural stem cells grafted into contusion-injured rat spinal cords improve behavior. *J Neurosci Res.* 2007;85:47-57.
50. Yan J, Xu L, Welsh AM, et al. Extensive neuronal differentiation of human neural stem cell grafts in adult rat spinal cord. *PLoS Med.* 2007;4:e39.
51. Amariglio N, Hirshberg A, Scheithauer BW, et al. Donor-derived brain tumor following neural stem cell transplantation in an ataxia telangiectasia patient. *PLoS Med.* 2009;6:e1000029.
52. Sashihara J, Tanaka-Taya K, Tanaka S, et al. High incidence of human herpesvirus 6 infection with a high viral load in cord blood stem cell transplant recipients. *Blood.* 2002;100:2005-2011.
53. van Burik JA, Brunstein CG. Infectious complications following unrelated cord blood transplantation. *Vox Sang.* 2007;92:289-296.
54. Vu T, Carrum G, Hutton G, Heslop HE, Brenner MK, Kamble R. Human herpesvirus-6 encephalitis following allogeneic hematopoietic stem cell transplantation. *Bone Marrow Transplant.* 2007;39:705-709.
55. Riddell SR, Appelbaum FR. Graft-versus-host disease: a surge of developments. *PLoS Med.* 2007;4:e198.
56. Marshall CT, Guo Z, Lu C, et al. Human adult olfactory neuroepithelial derived progenitors retain telomerase activity and lack apoptotic activity. *Brain Res.* 2005;1045:45-56.
57. Graziadei GA, Graziadei PP. Neurogenesis and neuron regeneration in the olfactory system of mammals. II. Degeneration and reconstitution of the olfactory sensory neurons after axotomy. *J Neurocytol.* 1979;8:197-213.
58. Graziadei PP, Karlan MS, Graziadei GA, Bernstein JJ. Neurogenesis of sensory neurons in the primate olfactory system after section of the fila olfactoria. *Brain Res.* 1980;186:289-300.
59. Paternostro MA, Meisami E. Quantitative [3H]thymidine autoradiography of neurogenesis in the olfactory epithelium of developing normal, hypothyroid and hypothyroid-rehabilitated rats. *Brain Res Dev Brain Res.* 1994;83:151-162.
60. Zhang X, Cai J, Klueber KM, et al. Role of transcription factors in motoneuron differentiation of adult human olfactory neuroepithelial-derived progenitors. *Stem Cells.* 2006;24:434-442.
61. Zhang X, Cai J, Klueber KM, et al. Induction of oligodendrocytes from adult human olfactory epithelial-derived progenitors by transcription factors. *Stem Cells.* 2005;23:442-453.
62. Au E, Roskams AJ. Olfactory ensheathing cells of the lamina propria in vivo and in vitro. *Glia.* 2003;41:224-236.
63. Li Y, Field PM, Raisman G. Olfactory ensheathing cells and olfactory nerve fibroblasts maintain continuous open channels for regrowth of olfactory nerve fibres. *Glia.* 2005;52:245-251.
64. Lakatos A, Smith PM, Barnett SC, Franklin RJ. Meningeal cells enhance limited CNS remyelination by transplanted olfactory ensheathing cells. *Brain.* 2003;126:598-609.
65. Dobkin BH. Progressive staging of pilot studies to improve phase III trials for motor interventions. *Neurorehabil Neural Repair.* 2009;23:197-206.